

Comparison of caudal steroid epidural with targeted steroid placement during spinal endoscopy for chronic sciatica: a prospective, randomized, double-blind trial

A. K. Dashfield*, M. B. Taylor, J. S. Cleaver and D. Farrow

Eric Angel Pain Management Centre, Level 07, Derriford Hospital, Plymouth PL6 8DH, UK

**Corresponding author. E-mail: adrian.dashfield@phnt.swest.nhs.uk*

Background. Chronic sciatica can be managed by caudal steroid epidural or by targeted steroid placement during spinal endoscopy. Spinal endoscopy is a new unproven procedure. We aimed to compare the two pain management techniques and to investigate whether the site of steroid placement within the epidural space was significant.

Methods. We randomized 60 patients with a 6–18 months history of sciatica to either targeted epidural local anaesthetic and steroid placement with a spinal endoscope or caudal epidural local anaesthetic and steroid treatment. Pre-treatment and 6-week, 3-month, and 6-month SF-MPQ and HAD scores were recorded.

Results. No significant differences were found between the groups for any of the measures at any time. However, there were significant differences within both groups compared with pre-treatment values. For the caudal group, significant improvements were found for descriptive pain at 6 months ($P=0.031$), VAS at 6 weeks ($P=0.036$), 3 months ($P=0.026$), and 6 months ($P=0.003$), present pain intensity (PPI) at 3 months ($P=0.013$) and 6 months ($P=0.01$); anxiety at 6 weeks ($P=0.008$), 3 months ($P=0.004$), and 6 months ($P=0.001$) and depression at 6 months only ($P=0.037$). For the epiduroscopy group there were fewer significant changes. PPI was significantly reduced at 6 weeks ($P=0.004$) and at 6 months ($P=0.02$). Anxiety was reduced at 6 months only ($P=0.03$).

Conclusion. The targeted placement of epidural steroid onto the affected nerve root causing sciatica does not significantly reduce pain intensity and anxiety and depression compared with untargeted caudal epidural steroid injection. When analysed individually, both techniques benefited patients.

Br J Anaesth 2005; **94**: 514–19

Keywords: anaesthetic techniques, epiduroscopy; complications, sciatica; treatment

Accepted for publication: December 8, 2004

The majority of patients who experience low back pain with sciatica recover after 4–8 weeks with the aid of simple analgesics and non-steroidal anti-inflammatory drugs.¹ About 10% of these patients go on to develop chronic radiculopathic pain, which can be difficult to treat. Epidural corticosteroid agents are commonly used in the treatment of low back pain and sciatica, although the efficacy of this treatment is controversial.^{2,3} Epiduroscopy has previously been reported to offer both diagnostic and therapeutic advantages compared with traditional epidural steroid administration techniques.^{4,5} Three recent prospective case series of patients undergoing therapeutic epiduroscopy with adhesiolysis of scar tissue and placement of corticosteroid around the affected nerve root reported beneficial outcomes.^{6–8} It has been postulated that the lack of positive

effects of epidural steroids in patients with radicular leg pain may in part be incorrect placement of injectate.⁶ To our knowledge no prospective randomized study has been published comparing a traditional method of delivering corticosteroid into the epidural space with targeted delivery during epiduroscopy.

Patients and methods

Patients

The study was approved by the local ethics committee and adhered to the Declaration of Helsinki. We recruited 60 patients presenting to the pain management centre at Derriford Hospital, Plymouth, UK between October 2001

and November 2003 in a prospective, randomized, double-blind study. We accept referrals from family doctors and other medical specialists. Patients were aged 18 yr or older, had sciatica defined as pain in the distribution of a lumbar nerve root, accompanied by neurosensory and motor deficits⁹ with or without back pain. Patients had sciatica for a minimum of 6 months but not for longer than 18 months. Patients who had previous spinal surgery, coagulopathy, progressive motor neurone disorders or peripheral vascular disease were excluded, as were patients who had received an epidural corticosteroid injection within 3 months of being randomized. We gave trial information sheets and obtained written informed consent after a full discussion about the nature of the study.

Procedures

Subjects were allocated randomly, using sealed envelopes, to either the caudal or epiduroscopy group. Both procedures were undertaken in the day-stay unit.

Subjects were placed prone on a horizontal operating table with a pillow placed under the pelvis and sedated with i.v. midazolam (0.1–0.15 mg kg⁻¹). Patients were sedated but awake and conscious. After sterile preparation of the surgical field, fluoroscopy was used for both procedures to introduce an 18-gauge Tuohy needle into the sacral hiatus. Needle position was confirmed by lateral x-ray and injection of contrast medium (Isovist 240®, Schering, UK) through the needle to verify position in the caudal epidural space.

Surgical drapes, i.v. sedation and the patient's prone position during the procedure enabled the patients to be blinded to which procedure was being undertaken.

Patients in the caudal group underwent caudal epidural corticosteroid injection with a total of 10 ml lidocaine 1% with 40 mg triamcinolone being injected into the epidural space.

Patients in the epiduroscopy group underwent epiduroscopy performed by an experienced epiduroscopist (A.K.D.). A 0.8-mm guide wire was inserted through the 18-gauge Tuohy needle under fluoroscopic guidance. A 4-mm diameter (8.5F) introducer (4005; Mylotec, Ruswell, GA, USA) with a dilator was advanced over the guide wire into the sacral epidural space. The dilator and guide wire were removed and the introducer was left in the sacral epidural space. A 0.9-mm endoscope (3000E; Mylotec) covered with a video-guided catheter (2000; Mylotec) was introduced via the introducer. The endoscope was gently advanced under direct vision in a cephalad direction. The vertebral level of the endoscope tip within the epidural space was confirmed by fluoroscopy. A constant flow of normal saline through the video-guided catheter enabled distension of the epidural space and a good visual field during the procedure.

The painful nerve root which corresponded to pre-operative clinical signs and radiographic examination was confirmed when patients reported worsened pain on endoscopic manipulation of the nerve root and 10 ml lidocaine

1% with triamcinolone 40 mg was instilled. The mean (range) total saline volume infused during the procedure was 132 (50 and 150) ml.

If adhesions were encountered around the painful nerve root, an attempt was made to break adhesions down using saline boluses or by manipulating the endoscope. Very little scar tissue was encountered in our patient population and adhesiolysis to access the pain generator was only necessary in three patients in the epiduroscopy group.

Our primary endpoints were 6-week, 3-month, and 6-month assessment of pain using the short-form McGill Pain Questionnaire¹⁰ (SF-MPQ) and anxiety and depression using the Hospital Anxiety and Depression scale (HAD).¹¹

Patient assessment and follow-up

Assessments were undertaken before treatment and at 6 weeks, 3 months, and 6 months following treatment. All patients were asked to complete the SF-MPQ and the HAD scale at this time. Patients who were unable to come to the clinic to complete their questionnaires were contacted by telephone by one of two blinded research nurses (J.C. and D.F.).

Complications and adverse effects were documented during clinic follow-up. Complications were defined as unpleasant, new, physical experiences for the patient such as post-spinal headache, worsened back pain and infection.

Statistical analysis

We analysed results on an intention-to-treat basis. Changes in variables were tested using the Mann–Whitney test as there was some evidence of non-normality. Patient characteristics were analysed using the χ^2 test for age, sex, height, weight, pre-treatment epidurals and pre-treatment pain duration, the Fisher's exact test for surgery, and Spearman's test for correlation between age and any of the measures. Comparison of pre-treatment scores with post-treatment scores for each group separately was undertaken using Wilcoxon (within-subjects) tests. A *P*-value of 0.05 was taken as significant.

In order to detect a 20% difference in the primary study endpoint (pain score) with $\alpha=5\%$ and $\beta=10\%$, a sample size of 30 patients in each group was found to be necessary.

The statistics software used was SPSS 11.5 for windows.

Results

The study population consisted of 60 patients. In three patients who were randomized to the epiduroscopy group access to the caudal canal for epiduroscopy proved technically impossible and they were given caudal epidural injections instead (Fig. 1). Patient characteristics (Table 1) were similar in the two groups. Baseline values were similar with the exception of SF-MPQ affective pain (*P*=0.039) and SF-MPQ present pain intensity (PPI) (*P*=0.013) (Table 2). In

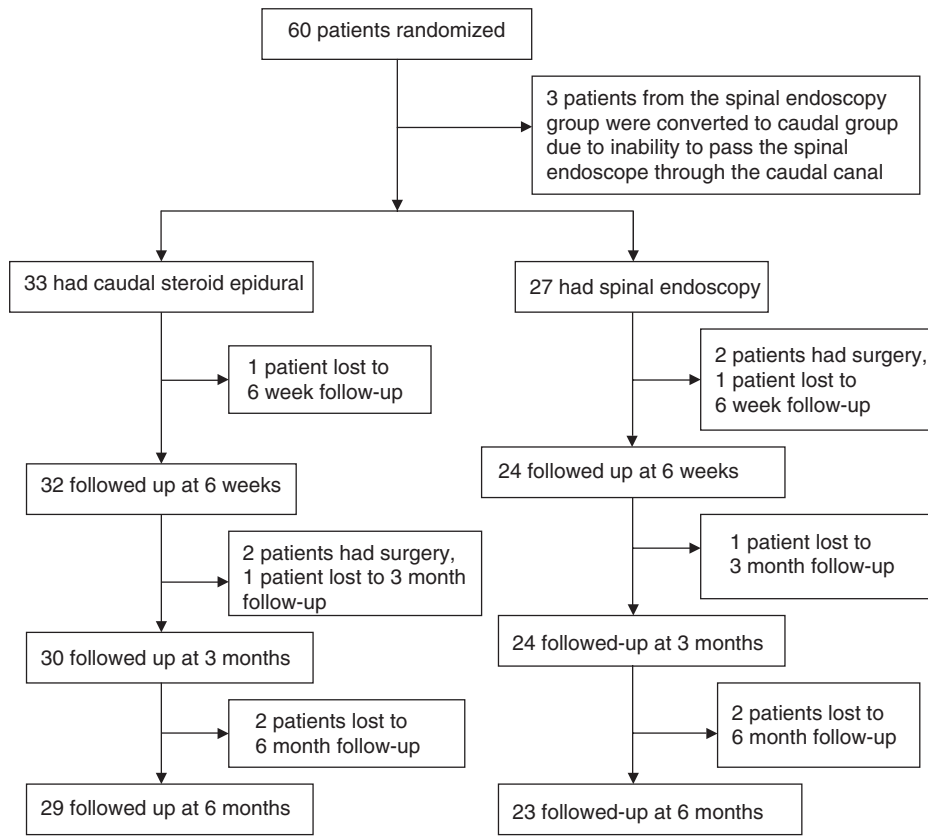


Fig 1 Trial profile.

Table 1 Patient characteristics

	Caudal (n=33)	Epiduroscopy (n=27)
Age (yr): mean (range)	47.5 (24–84)	44.8 (25–74)
Height (cm): mean (SD)	164 (7)	165 (9)
Weight (kg): mean (SD)	68 (13)	71 (11)
Gender: no. (%)		
Male	17 (51.5)	10 (37)
Female	16 (48.5)	17 (63)
Patients withdrawing to receive surgery: no. (%)	2 (6)	2 (7)
Duration of pain before entering study (months): mean (range)	9.4 (6–17)	10.1 (7–18)
No. of patients having epidural steroids before randomization no. (%)	3 (9)	2 (7)
Duration of procedure (min): mean (range)	12 (8–21)	45 (40–57)

both cases the highest median and mean was for the epiduroscopy group, which arose by chance.

Of the 60 patients enrolled into this study, 16 had undergone lumbar MRI scan before recruitment. Clinical signs and symptoms matched radiological findings in 12 of these patients (75%).

The two groups were compared using the differences from pre-treatment values. No significant differences were found

Table 2 Outcomes of follow-up periods. Short Form McGill Pain Questionnaire, SF-MPQ. Hospital Anxiety and Depression Scale, HAD. *P<0.05 compared with the baseline value

	Baseline	Follow-up		
		6 weeks	3 months	6 months
Caudal group				
Visual analogue score (cm): mean (SD)	6.6 (1.7)	5.7 (2.8)*	5.4 (2.9)*	5.2 (2.73)*
SF-MPQ (sensory): mean (SD)	14.8 (7.1)	13.9 (8.0)	13.1 (9.0)	12.5 (8.0)*
SF-MPQ (affective): mean (SD)	4.2 (3.2)	4.7 (3.5)	4.6 (3.5)	4.2 (3.3)
Present pain intensity (PPI): mean (SD)	2.8 (1.0)	2.3 (1.3)	2.1 (1.5)*	2.0 (1.2)*
HAD scale–anxiety (/21): mean (SD)	10.9 (6.4)	9.3 (6.7)*	8.4 (7.2)*	7.8 (6.8)*
HAD scale–depression (/21): mean (SD)	8.4 (3.5)	8.2 (4.0)	7.7 (3.9)	7.0 (4.1)*
Epiduroscopy group				
Visual analogue score (cm): mean (SD)	7.22 (1.8)	6.7 (2.3)	6.4 (3.0)	6.0 (3.3)
SF-MPQ (sensory): mean (SD)	15.5 (6.7)	16.0 (6.7)	16.4 (7.9)	16.0 (9.7)
SF-MPQ (affective): mean (SD)	5.9 (3.4)	4.9 (3.4)	6.6 (3.6)	5.9 (3.8)
Present pain intensity (PPI): mean (SD)	3.5 (1.34)	2.6 (0.88)*	3.1 (1.4)	2.5 (1.4)*
HAD scale–anxiety (/21): mean (SD)	10.33 (4.3)	10.0 (4.1)	9.6 (2.9)	8.7 (4.5)*
HAD scale–depression (/21): mean (SD)	9.0 (3.5)	8.0 (4.0)	8.0 (3.4)	7.9 (4.3)

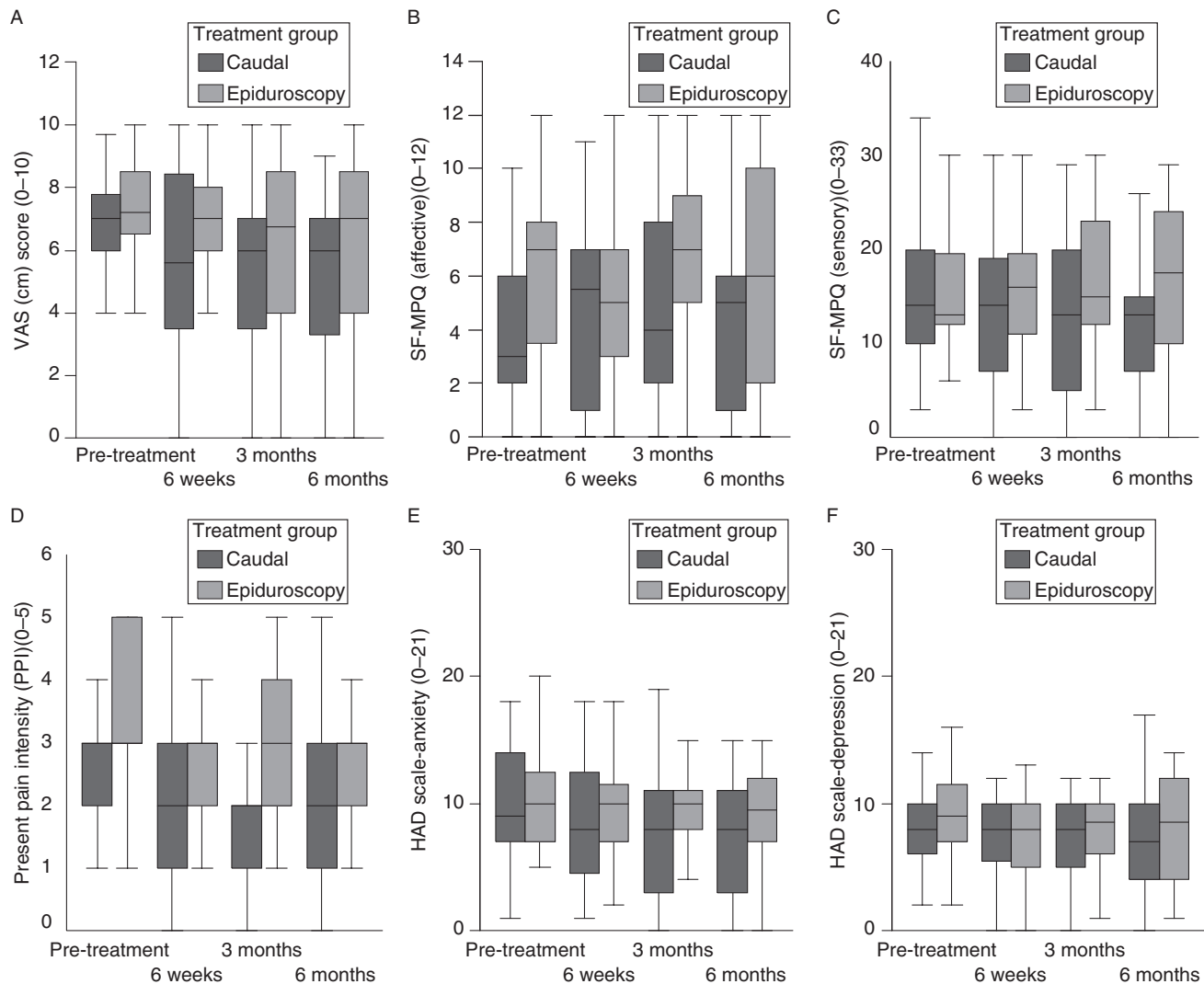


Fig 2 Box and whisker plot for (A) VAS scores, (B) SF-MPQ (affective), (C) SF-MPQ (sensory), (D) PPI, (E) HAD-anxiety, and (F) HAD-depression. The horizontal line with the box represents the median value and the top and bottom boundaries of the box represent the 25th and 75th percentiles, respectively. No significant difference.

between the groups for any of the measures at any of the times (Table 2).

The data were further analysed to compare the pre-treatment scores with the various post-treatment scores for each group separately (Fig. 2). For the caudal group, significant changes were found between post- and pre-treatment for descriptive pain at 6 months ($P=0.03$), VAS at 6 weeks ($P=0.034$), 3 months ($P=0.026$), and 6 months ($P=0.003$), PPI at 3 months ($P=0.01$) and 6 months ($P=0.01$); anxiety at 6 weeks ($P=0.008$), 3 months ($P=0.004$) and 6 months ($P=0.001$) and depression at 6 months only ($P=0.04$). For the epiduroscopy group there were fewer significant changes between post- and pre-treatment. PPI at 6 weeks was significantly reduced ($P=0.004$) and at 6 months ($P=0.02$). Anxiety was reduced at 6 months only ($P=0.03$).

Complications encountered were some non-persistent post-procedure low back discomfort in all patients in the

epiduroscopy group, and in fewer patients in the caudal group. This was insufficient to require admission to hospital in either treatment group and responded to simple analgesic medication. No patients reported post-spinal headache and no dural tap was knowingly caused. There were no cases of post-procedure infection.

Discussion

In this study we were unable to demonstrate a significant advantage of spinal endoscopic placement of steroid compared with caudal epidural steroid in patients with sciatica using the SF-MPQ and HAD scale as primary outcome measures. The theoretical advantages of spinal endoscopy that allows identification of the nerve root responsible for pain generation and accurate placement of local anaesthetic and steroid were not translated into clinical practice in our study.

When each treatment group was viewed separately, patients in both groups benefited from their respective treatments, the caudal group showing greater, but not statistically significant, benefit compared with the epiduroscopy group. This, however, may be a reflection of the smaller number of patients in the epiduroscopy group compared with the caudal group.

Our study was designed to investigate whether the site of epidural corticosteroid placement within the epidural space was important. Most patients recover within 6–8 weeks following an episode of radicular leg pain. We chose 6 months as the minimum period for patients to be symptomatic as we thought spontaneous recovery to be unlikely after this period.

Patients with failed back surgery syndrome and symptomatic lumbar spinal stenosis frequently have large amounts of scar tissue surrounding nerve roots,^{6–8} which forms as a result of extrusion of nucleus pulposus, chronic chemical radiculitis, nerve root inflammation, and following surgical bleeding from spinal surgery.^{12–15} Epidural scar tissue is thought to interfere with nerve root nutrition and blood supply^{12 15 16} and prevents the steroid solution from coming into contact with the nerve root. For this reason we excluded patients with previous spinal surgery and chronic lumbar spinal stenosis. We chose an 18-month history of radiculopathy as an arbitrary maximum period for enrolment.

We decided not to rely on computerized tomography (CT) and magnetic resonance imaging (MRI) scanning in diagnosing lumbar radiculopathy as these investigations are fraught with diagnostic false positives and false negatives.¹⁷ Instead we relied on history and physical examination in combination with scan results if available, to decide whether patients were suitable for inclusion in our study.

Very little scar tissue was encountered in our study patients undergoing epiduroscopy. In common with Richardson's study⁶ the pain generator was identified in all the patients in the epiduroscopy group.

Previous studies have highlighted adhesiolysis as being one of the advantages of epiduroscopy.^{6–8} Mechanical dissection of scar tissue at the level of the affected nerve root with the tip of the endoscope and constant instillation of saline may allow restoration of blood supply and nerve root nutrition with possible pain relief and nerve root recovery. Only three patients in the epiduroscopy group required adhesiolysis to access the painful nerve root. Our study did therefore not investigate the value of mechanical or chemical adhesiolysis.

Recent UK guidance by the National Institute of Clinical Excellence (NICE)¹⁸ noted that 'currently evidence for endoscopic division of epidural adhesions is inadequate for this procedure to be used without special arrangements for consent and for audit or research'. NICE will review its recommendations upon publication of further evidence.

Several groups have reported the importance of inflammatory mediators in causing low back pain and leg pain.^{16 19 20} Previous workers have suggested that the effect

of saline in diluting local tissue concentrations of inflammatory mediators during spinal endoscopy may result in pain relief.^{6–8} Our study did not support this finding. This may be because of the relatively small volume of saline we used during spinal endoscopy compared with other studies.

Spinal endoscopy appears to be a safe procedure. In common with other studies^{6–8} only minor side effects resulted in our study. It has great value in the diagnosis of nerve root pathology and is more sensitive than gadolinium enhanced MRI²¹ for visualizing scar tissue.

We did not show that targeted placement of corticosteroid onto the affected nerve root was superior to caudal steroid epidural. The role of epiduroscopic adhesiolysis in patients with epidural scar tissue affecting nerve root nutrition warrants further investigation.

Acknowledgements

The Defence Secondary Care Agency funded this study. The study sponsor had no role in study design, data collection, data analysis, data interpretation, or writing of the report. We would like to thank the nurses of the Freedom day case unit at Derriford Hospital, Plymouth for their assistance, Dr J. Langton, Honorary Reader, Peninsula Medical School for his assistance with proofreading the manuscript and Dr S. Shaw, Senior Lecturer, Department of Mathematics and Statistics, University of Plymouth, for his assistance with the statistical analysis.

References

- 1 Weber H, Holme I, Amlie E. The natural course of acute sciatica with nerve root symptoms in a double blind, placebo controlled trial evaluating the effect of piroxicam. *Spine* 1993; **18**: 1433–8
- 2 Watts RW, Silagy CA. A meta-analysis on the efficacy of epidural corticosteroids in the treatment of sciatica. *Anaesth Int Care* 1995; **23**: 564–9
- 3 McQuay HJ, Moore RA. Epidural steroids for sciatica. *Anaesth Int Care* 1996; **24**: 284–5
- 4 Saberski L. A retrospective analysis of spinal canal endoscopy and laminectomy outcome data. *Pain Physician* 2000; **3**: 193–6
- 5 Manchikanti L, Pakanati R, Pampati V, Fellows B. The value and safety of epidural endoscopic adhesiolysis. *Am J Anesthesiol* 2000; **27**: 275–9
- 6 Richardson J, McGurgan P, Cheema S, Prasad R, Gupta S. Spinal endoscopy in chronic low back pain with radiculopathy. A prospective case series. *Anaesthesia* 2001; **56**: 447–84
- 7 Igarashi T, Hirabayashi Y, Seo N, Saitoh K, Fukuda H, Suzuki H. Lysis of adhesions and epidural injection of steroid/local anaesthetic during epiduroscopy potentially alleviate low back and leg pain in elderly patients with lumbar spinal stenosis. *Br J Anaesth* 2004; **93**: 181–7
- 8 Geurts JW, Kallewaard J-W, Richardson J, Groen GJ. Targeted methylprednisolone acetate/hyaluronidase/clonidine injection after diagnostic epiduroscopy for chronic sciatica: a prospective 1-year follow-up study. *Reg Anes Pain Med* 2002; **27**: 343–52
- 9 Frymoyer JW. Back pain and sciatica. *N Engl J Med* 1988; **318**: 291–300
- 10 Melzack R. The short-form McGill Pain Questionnaire. *Pain* 1987; **30**: 191–97
- 11 Zigmond AS, Snaith RP. The Hospital Anxiety and Depression Scale. *Acta Psychiatr Scand* 1983; **67**: 361–70
- 12 Olmarker K, Rydevik B, Nordborg C. Autologous nucleus pulposus induces neurophysiologic and histologic changes in porcine cauda equina nerve roots. *Spine* 1993; **18**: 1425–32

- 13 Hasue M. Pain and the nerve root. An interdisciplinary approach. *Spine* 1993; **18**: 2053–8
- 14 Otani K, Arai I, Mao PG, Konno S, Olmarker K, Kikuchi S. Experimental disc herniation. Evaluation of the natural course. *Spine* 1997; **22**: 2894–9
- 15 Kayama S, Konno S, Olmarker K, Yabuki S, Kikuchi S. Incision of the annulus fibrosus induces nerve root morphologic, vascular and functional changes. An experimental study. *Spine* 1996; **21**: 2539–43
- 16 Rydevik B, Brown M, Lundborg G. Pathoanatomy and pathophysiology of nerve root compression. *Spine* 1984; **9**: 7–15
- 17 Devulder J, Bogaert L, Castille F, Moerman A, Rolly G. Relevance of epidurography and epidural adhesiolysis in chronic failed back surgery patients. *Clin J Pain* 1995; **11**: 147–50
- 18 Endoscopic division of epidural adhesions. www.nice.org.uk/IPG088guidance
- 19 Garfin S, Rydevik B, Lind B, Massie J. Spinal nerve root compression. *Spine* 1995; **20**: 1810–20
- 20 Nachemson A. Intradiscal measurements of pH in patients with lumbar rhizopathies. *Acta Orthop Scand* 1969; **40**: 23–42
- 21 Wilkinson LS, Elson E, Saifuddin A, Ransford AO. Defining the use of gadolinium enhanced MRI in the assessment of the post-operative lumbar spine. *Clin Radiol* 1997; **52**: 530–4